

Management of Puberty Associated Gingival Enlargement in an Adolescent Female - A Case Report with a Follow-Up of 1 Year

Dr. Lashika V. Tambe¹, Dr. Mala Dixit Baburaj²

¹Post-graduate student, Dept of Periodontics, Nair Hospital Dental College, Mumbai, Maharashtra state

² Head of department, Dept of Periodontics, Nair Hospital Dental College, Mumbai, Maharashtra state

Abstract: Sex hormones have long been considered to play an influential role on the periodontal tissue, bone turn-over rate, wound healing and periodontal disease progression. The onset of puberty can bring about changes in the hormonal levels which in turn may affect the gingival tissues in both males and females leading to altered tissue response to dental plaque and can lead to conditioned gingival enlargement. Such overgrowths can bring about various problems like difficulty in speech, bleeding gums and even aesthetic problems. Oral Health care professionals have better awareness as well as better capabilities for dealing with hormonal influences associated with the reproductive process. In the current case report, we have discussed the management of a Puberty Associated gingival overgrowth in the maxillary anterior region in a young adolescent female.

Keywords: Conditioned enlargement, Estrogen, Gingivectomy, Progesterone, Puberty

1. Introduction

Throughout a woman's life cycle, hormonal influences affect the therapeutic decision making in Periodontics. Historically therapies have been gender biased. Therefore it is imperative that the clinician should recognize, customize and appropriately alter the periodontal therapy to the individual woman's needs based on the stage of her life cycle. The homeostasis of the periodontium involves complex multifactorial relationships, in which the endocrine system plays an important role [1]. Hormones are specific regulatory molecules that modulate function reproduction, growth and development and the maintenance of internal environments as well as energy production, utilization and storage [1]. Under the broad category of dental plaque induced gingival diseases that are modified by systemic factors those associated with the endocrine system, are classified as puberty, menstrual cycle and pregnancy associated gingivitis [2]. Researchers have shown that changes in periodontal conditions may be associated with variations in sex hormones [3]. Puberty occurs between the average age group of 11-14 years of age. It is a complex process of sexual maturation resulting in an individual capable of reproduction, induces changes in physical appearance and behavior that is the direct result of increase in sex steroid hormones, primarily testosterone in males and estradiol in females [4,5]. At puberty, the production of sex hormones (estrogen and progesterone) increases to a level that remains relatively constant throughout the normal female reproductive phase. In the gingiva, these steroid hormones can influence the cell division, growth and differentiation of fibroblasts and keratinocytes. Alterations in blood vessels is mostly caused by estrogen and stimulation of the production of inflammatory mediators mainly by progesterone [5].

Clinical and microbiological changes during puberty includes-

- 1) Exaggerated gingival inflammation without accompanying an increase in plaque levels.
- 2) Increased prevalence of certain species like Prevotella intermedia and Capnocytophaga.

Kornman and Loesche postulated that these anaerobic organisms may use ovarian hormones as a substitute for vitamin K growth factor [6]. Both organisms are believed responsible for the increased bleeding tendency noted in puberty.

Signs and symptoms-

- 1) A hyperplastic reaction of the gingiva may occur in areas where food debris, materialalba and plaque and calculus deposits.
- 2) The inflamed tissue become erythematous, lobulated and retractable.
- 3) Bleeding occurs easily during mechanical debridement.
- 4) Histologically the appearance is consistent with inflammatory hyperplasia.

Thus maintenance of proper oral hygiene is the key in the management of such types of conditions. In this case report, we present a typical case of puberty associated gingival enlargement and emphasize the importance of taking a proper history in achieving a correct diagnosis and formulating a proper treatment plan in such cases.

2. Case Report

A 14 year old female patient reported to the out-patient department of Department of Periodontics, Nair Hospital Dental College, Mumbai with a chief complain of swollen gums in the upper and lower front teeth region since 1 year. The growth gradually kept increasing in size since its inception to its noticeable current size. It was associated with bleeding from gums on brushing. The medical history

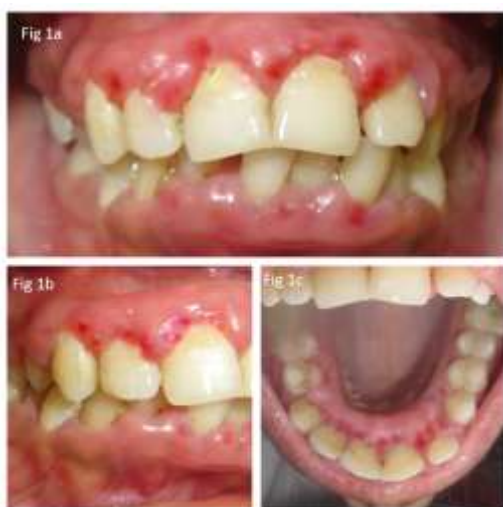revealed that the patient started menstruating before 1 year, and the gums had started swelling up almost concomitant with it. The patient had not undergone any dental treatment before. The patient did not have any deleterious habits. She brushes once daily using medium bristled toothbrush and fluoridated toothpaste with horizontal scrub toothbrushing technique.

On intraoral examination, a reddish pink bulging of the interproximal papillae with blunt and rounded marginal gingiva was found on the facial and palatal/lingual surface extending from the distal surface of 13 to distal surface of 23 in maxilla and mesial surface of 33 to mesial surface of 43 in mandible. The gingiva was enlarged, soft, edematous and friable and bled on the slightest provocation. There was a presence of some amount of marginal plaque and calculus.

severity of the disease .They were motivated and educated for taking proper oral hygiene measures. A routine oral prophylaxis was performed for the patient. She was advised to brush her teeth twice daily using Modified Bass technique. She was instructed to rinse twice with 5 ml of 0.2% Chlorhexidine mouthrinse for 1 min everyday for 2 weeks. The patient was recalled after every 2 weeks for a period of 2 months.

Re-evaluation-

On re-evaluation, the inflammatory component of the enlarged gingiva had subsided but there was still a presence of fibrous component that compromised the routine oral hygiene measures .Hence we decided to perform Gingivectomy to excise the bulge of the tissue and create cleansable areas in the oral cavity.



Pre-operative view

Mirror test- A double sided mirror was held between the nose and mouth .As the patient was breathing fogging appeared on the nasal side of the mirror. This indicated that the patient was a nasal breather.

Investigations:

- 1) IOPA showed moderate horizontal bone loss with respect to maxillary and mandibular anterior teeth region.
- 2) Lab investigations for complete blood counts and hormone level for circulating estradiol, stimulating follicular hormone, luteinizing hormone were advised, which came out to be within normal limits with hormone level coinciding with the pubertal age.

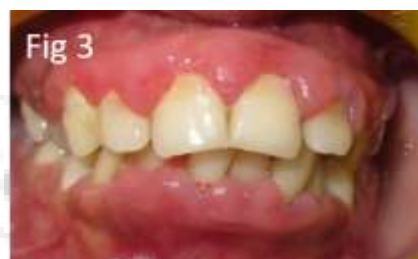Hence, the diagnosis of pubertal gingival enlargement was made as the enlargement was initiated at around puberty.



Iopa showing horizontal bone loss

Phase I Therapy-

The patient and her parents were made aware about the

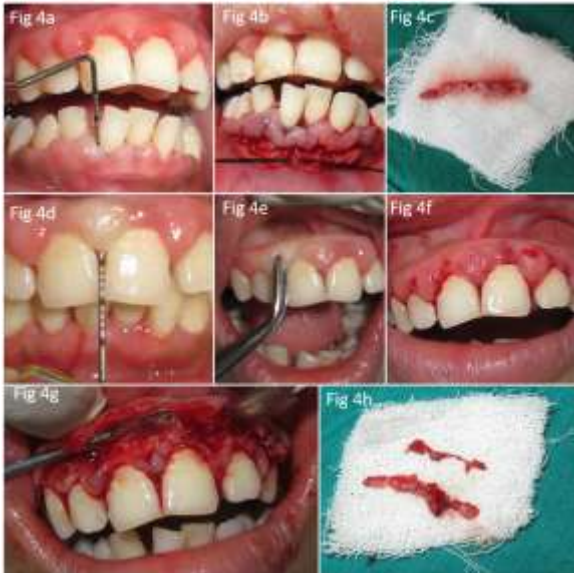

Recall after 2 months of Phase 1 therapy

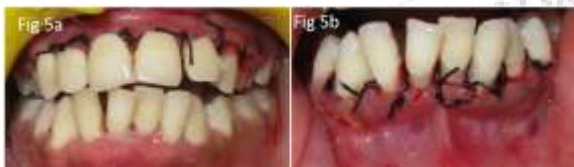Phase 2 Therapy-

Informed consent was taken from the patient and her parents before starting the surgical procedure. Patient was infiltrated with 2 % Lignocaine and adrenaline (1:200000).Periodontal examination with the help of UNC-15 probe revealed a pocket depth of 5-6 mm in maxillary and mandibular anterior teeth region. A pocket marker was used to mark the bleeding points corresponding to the pocket depth on the facial and lingual/palatal surface. A #15 blade was used to perform an internal bevel incision from the bleeding point towards the alveolar bone. Internal bevel gingivectomy was performed and subgingival debridement was done after flap reflection. The flaps were sutured with interrupted suture technique using 4-0 silk suture. Periodontal dressing (Coe-Pak) was applied over the surgical area. The patient was prescribed antibiotic (Cap. Amoxicillin 500mg Tid) and analgesic (Tab. Diclofenac 50mg Bid) for 3 days. Patient was advised to intermittently apply ice extra-orally at the surgical site. She was asked to use 0.2 % Chlorhexidine mouthrinse twice daily for 1 week .The patient was recalled after 8days.

The excised tissue was sent to the Department of Oral Pathology for histopathological examination.



Internal level gingivectomy performed in mandibular and maxillar anterior teeth region



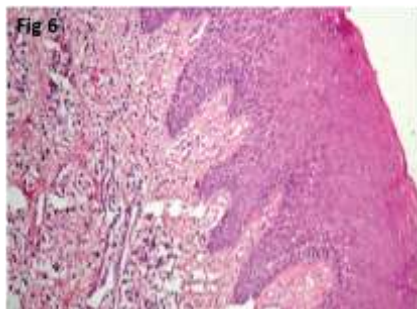
Sutures placed with 4-0 silk suture with interrupted suturing technique

Re-evaluation-

Recall visit after 8 days showed uneventful healing of the surgical site. A 2 mm recession was seen with respect to 31, 32 and 41. Patient was reinforced with oral hygiene instruction .She was advised warm saline rinse everyday for 3-4 times. The patient was kept on a frequent follow- up every 15 days for 2 months and then every 3 months for a year.

Histopathological examination-

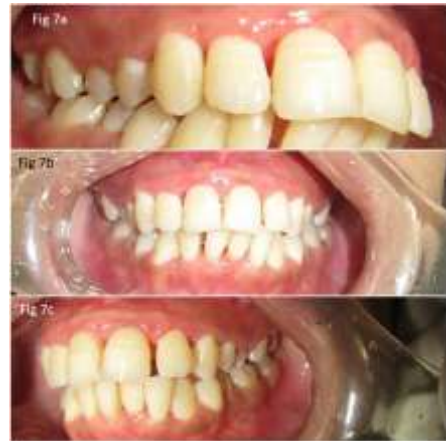Histopathological examination showed parakeratinized stratified squamous epithelium with densely arranged collagen fibers in the underlying connective tissue. Marked inflammatory edema and predominance of lymphocytes in addition to other inflammatory cells were observed all suggestive of inflammatory enlargement.



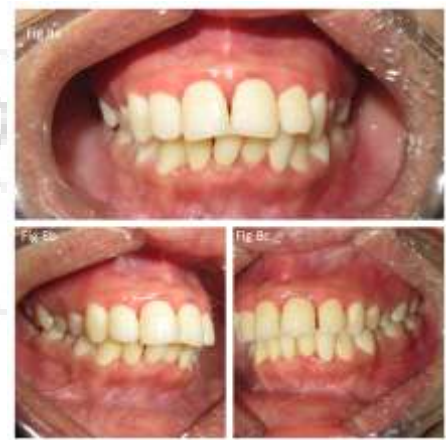Histopathology showing inflammatory gingival hyperplasia

Recall after 3 months showed significant improvement in the health of the gingival tissues .The pocket depth was reduced

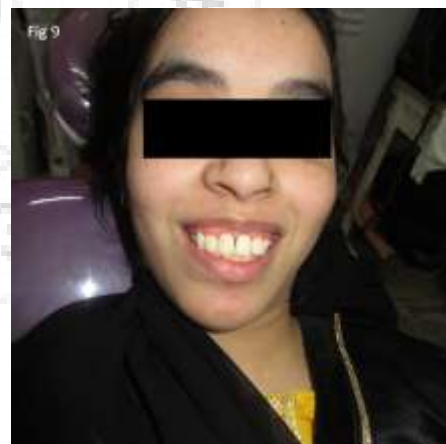and maintainable areas were created.



Recall after 3 months



Recall after 6 months



Recall after 1 year

3. Discussion

Puberty is a complex process of sexual maturation, and it is responsible for changes in physical appearance and behavior that are related to increased levels of the sex steroid hormone estradiol in females. At this time, there is a marked increase in Testosterone levels in males and Estrogen and Progesterone in females [7]. A study conducted by Sutcliffe P and colleagues showed a peak prevalence of gingivitis at 12 years, 10 months in females and 13 years, 7 months in males, which is consistent with the onset of puberty [8]. On

Careful history taking, it was found that our patient also had started observing her gum swelling and bleeding gums when she was 13 years of age, and it also coincided with the onset of her puberty. During puberty, education of the parent or caregiver is an integral part of successful periodontal therapy. Preventive care, including vigorous implementation of oral hygiene, is vital for maintaining periodontal health. Milder cases of gingivitis in puberty respond well to scaling and deplaquing, along with frequent oral hygiene reinforcement [9]. Severe cases of this type of gingivitis may require microbial culture, antimicrobial mouthwashes and local site delivery of an antiseptic. Periodontal maintenance appointments may need to be more frequent when there is an apparent risk of periodontal disease progression [10]. The clinician should also recognize that the incidence of asthma and/or mouth breathing may be higher in pubertal female and male subjects. The incidence of asthma also increases after puberty in female subjects. This may cause gingival enlargement, especially in the anterior area of the dentition, possibly as a result of surface dehydration. The clinician should recommend meticulous home care and increase the frequency of periodontal maintenance appointments and dental caries evaluation. Topical application of an occlusive barrier (lubricant) over the inflamed gingiva after home-care procedures and immediately before bedtime may aid in the reduction of soft-tissue edema. Female adolescents (11–14 years of age) are susceptible to problems associated with eating disorders. The clinician should examine for intra-oral signs and symptoms of anorexia nervosa and bulimia nervosa in a suspect patient. Chronic regurgitation of gastric contents will appear as perimylosis (i.e. smooth erosion of enamel and dentin), typically on the lingual surfaces of maxillary anterior teeth, and the duration and frequency of the behavior will determine the degree of perimylosis [11]. Also, enlargement of the parotid glands (occasionally sublingual glands) has been estimated to occur in 10–50% of patients who binge and purge [12]. Therefore, a diminished salivary flow rate may also be present, which will increase oral mucous membrane sensitivity, gingival erythema and caries susceptibility. Oral healthcare providers are often the first to recognize eating disorders. After consultation with the patient and/or parent, a referral to a physician, psychologist or nutritional consultant is advised.

4. Conclusion

The female patient presents unique complexities that vary along her life's continuum. The cyclic nature of the female sex hormones is often reflected in the gingival tissues as initial signs and symptoms. Medical history and dialogs should include thoughtful investigation of the individual patients needs. Hormonal fluctuations differ from patient to patient. Patients should be educated regarding the profound effects that sex hormones may play on periodontal and oral tissues. Strict oral hygiene maintenance is of prime importance for the patient because it is the dental plaque that leads to incidence and prevalence of disease while the level of hormone modifies the response.

References

- [1] Mariotti A (1994) Sex steroid hormones and cell dynamics in the periodontium. *Crit Rev Oral Biol Med* 5(1): 27-53.
- [2] Armitage GC (1999) Development of a classification system for periodontal diseases and conditions. *Ann Periodontol* 4(1): 1-6.
- [3] Plancak D, Vizner B, Jorgic-Srdjak K (1998) Endocrinological status of patients with periodontal disease. *Coll Antropol* 22: 51-55.
- [4] Jafri Z, Bhardwaj A, Sawai M, Sultan N. Influence of female sex hormones on periodontium: A case series. *J Nat Sc Biol Med* 2015;6:S146-9.5.
- [5] Eleni Markou, Boura Eleana, Tsalikis Lazaros and Konstantinides Antonios The Influence of Sex Steroid Hormones on Gingiva of Women The *Open Dentistry Journal*, 2009, 3, 114-119
- [6] Kornman K, Loesche JF: Direct interaction of Estradiol and Progesterone with *bacteroides melanogenicus* *J. Dent Res* 58A :10, 1979.
- [7] GN Güncü, TF Tözüm, F Çağlayan. Effects of endogenous sex hormones on the periodontium –Review of literature. *Australian Dental Journal* 2005;50:(3):138-145
- [8] Sutcliffe P. A longitudinal study of gingivitis and puberty. *J PeriodRes* 1972; 7: 52-8.
- [9] American Dental Association Council on Access, Prevention, and Interprofessional Relations. Women's oral health issues. Chicago, IL: American Dental Association, 1995.
- [10] Otomo-Corgel J. Systemic considerations for female patients. In: Newman MG, van Winkelhoff AJ editors. Antibiotic and antimicrobial use in dental practice. Chicago, IL: Quintessence Pub. Co., 2001: 636–649.
- [11] Brown S, Bonifazi DZ. An overview of anorexia and bulimia nervosa, and the impact of eating disorders on the oral cavity. *Compendium* 1993; 14: 1594, 1596–1602, 1604–1608.
- [12] Mandel L, Kaynar A. Bulimia and parotid swelling: a review and case report. *J Oral Maxillofac Surg* 1992; 50: 1122–1125.