

Multidisciplinary Management of An Unusual Isolated Alveolar Bone Infection- A Rare Case Report

PIMPALÉ SANDEEP K¹, DIXIT MALA B², KULKARNI RAHUL S³, RAMUGADE MANOJ M⁴

ABSTRACT

Restoration of proximal defect of tooth is of paramount importance as its improper restoration usually results in fracture of the restoration or deteriorated periodontal health. The article reports a case with a discreet mass of alveolar bone necrosis closed to the overhanged amalgam restoration in the proximal box of the maxillary molar. As a result of this improper proximal restoration it led to deep periodontal pocket and subsequent alveolar bone necrosis which was managed successfully with combined Endodontic-Periodontic treatment. This article highlights the unfortunate sequelae of bone necrosis as a consequence of an incorrect or overlooked dental treatment and its comprehensive management.

Keywords: Amalgam restoration, Endodontic-periodontic lesion, Osteonecrosis, Periodontal regeneration.

CASE REPORT

A healthy 23-year-old male patient reported to the Department of Periodontics, with a chief complaint of dull, continuous pain and discomfort in the left maxillary posterior tooth since a month which gradually increased. On clinical examination, it was evident that the tooth #26 had Class II silver amalgam restoration. The restoration was overcontoured and overextended in the mesio-occlusal proximal region with a loss of interdental papilla between tooth #25 and tooth #26. When the concerned area was probed with UNC-15 periodontal probe, there was bleeding on probing evident with presence of 11 mm periodontal pocket [Table/Fig-1]. The overall hygiene of the patient was good except for the maxillary left posterior region. The patient had no relevant systemic medical history. As per the dental history provided by the patient, the amalgam restoration was placed after root canal treatment, six months ago when the patient had reported to a private dental clinic for a carious lesion in relation to the tooth #26. The patient experienced a dull continuous pain in the mentioned region since then, but the patient didn't report to the dentist again as the discomfort was tolerable. But recently, when the discomfort increased, he reported to the department.

An Intra oral periapical radiographic assessment of tooth (#26) showed following findings-

- 1) Radio-opaque, underfilled root canal obturating material within the canals associated with periapical radiolucency and coronal post endodontic restoration in mesio-occlusal proximal aspect of tooth #26.
- 2) Mesial overhanging restoration which was directly encroaching on the underlying interdental bone.
- 3) A small, irregular radio-opaque mass surrounded by an ill-defined radiolucency was observed in interdental region of tooth #25 and tooth #26, suggestive of separated alveolar bone from the underlying resorbed alveolar bone [Table/Fig-2a&b].

Treatment procedure

After thorough clinical and radiological examination along with the past dental history of the patient, it was diagnosed as a case of alveolar bone necrosis subsequent to faulty amalgam restoration. The treatment plan was formulated and explained to the patient.

Treatment plan

Step 1 – To remove the faulty amalgam restoration followed by re-root canal treatment with the involved tooth #26.

Step 2 – A periodontal flap surgery was planned to remove necrosed part of bone, eliminate the periodontal pocket and correct the underlying hard and soft tissue defect.

After taking informed consent of the patient, local anaesthesia (2 % Lignocaine Hydrochloride with 1: 100, 000 Adrenaline) was administered and old faulty amalgam restoration was removed with air-rotor and water coolant coupled with high vacuum suction. Tooth #26 was isolated under rubber dam and proper access cavity preparation was done. The underfilled gutta percha obturation material was removed with NO. 30- H (Hedstrom) files. Thorough cleaning and shaping of the root canals was done using Protaper universal rotary files and canal irrigated with 5.25% sodium hypochlorite. Three located canals were obturated with Protaper Gutta percha and Resin sealer. Post obturation, the silver amalgam restoration was done after 5 days.

After 7 days, a full thickness periodontal flap was reflected under local anaesthesia for the involved tooth #26. After reflection of flap, a substantial amount of granulation tissue was seen and within it was embedded the necrosed interdental bone. Post thorough debridement, the isolated bone fragment could be appreciated which was brownish in colour and was completely separated from the underlying healthy bone [Table/Fig-3a]. The acquired bone fragment was sent for histopathological examination. Flap was sutured with Black silk sutures (3-0) [Table/Fig-3b] after copious irrigation with 10% povidone iodine and saline. Periodontal dressing (Coe pak) was placed. After a week, the patient reported for suture removal. After suture removal, the patient followed up for prosthetic treatment. A porcelain fused to metal crown was placed after tooth preparation. Additionally, the patient was instructed and demonstrated for use of interdental proxa brush to maintain in the area. The patient was recalled on regular intervals for check up.

After one and a half months of recall when examined clinically, it was evident that the probing pocket depth was persistent and it was difficult for the patient to maintain oral hygiene in the area of tooth #26 due to the presence of underlying defect [Table/Fig-4]. The crown placed with tooth #26 was fabricated with smooth and polished margins and was placed supragingivally. Hence, it could not act as a contributory factor to plaque built up. Moreover, the persistent pocket was the result of the underlying bony defect. So, a second surgery was planned not merely to eliminate the periodontal pocket but also to access and treat the bony defect caused as

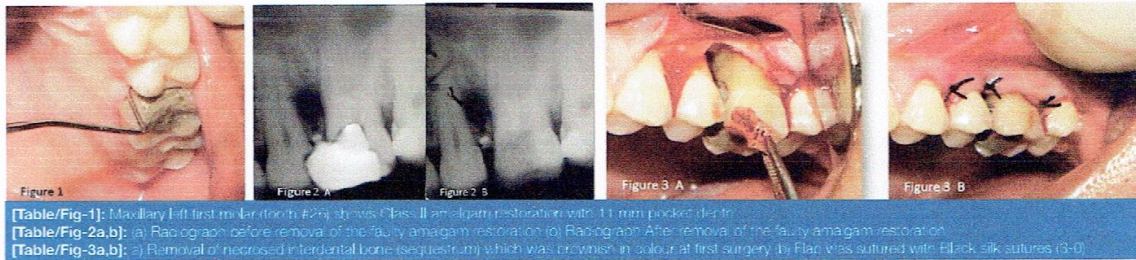


Figure 1

Figure 2 A

Figure 2 B

Figure 3 A

Figure 3 B

[Table/Fig-1]: Maxillary left first molar (tooth #29) shows Class II amalgam restoration with 11 mm pocket depth.

[Table/Fig-2a,b]: (a) Radiograph before removal of the faulty amalgam restoration (b) Radiograph After removal of the faulty amalgam restoration.

[Table/Fig-3a,b]: (a) Removal of necrosed interdental bone (sequestrum) which was brownish in colour at first surgery. (b) Flap sutured with black silk sutures (3-0).




Figure 4

Figure 5 A

Figure 5 B

Figure 6 A

Figure 6 B

[Table/Fig-4]: Probing pocket depth present at 45 days recall.

[Table/Fig-5a,b]: (a) Full thickness mucoperiosteal flap reflected at second surgery (b) DFDBA (Bone Allograft) & PERIOCOL GTR Regenerative Membrane (Resorbable).

[Table/Fig-6a,b]: (a) Placement of Bone graft & Periodontal regenerative membrane at second surgery (b) Periodontal membrane secured with VICRYL resorbable sutures (3-0).

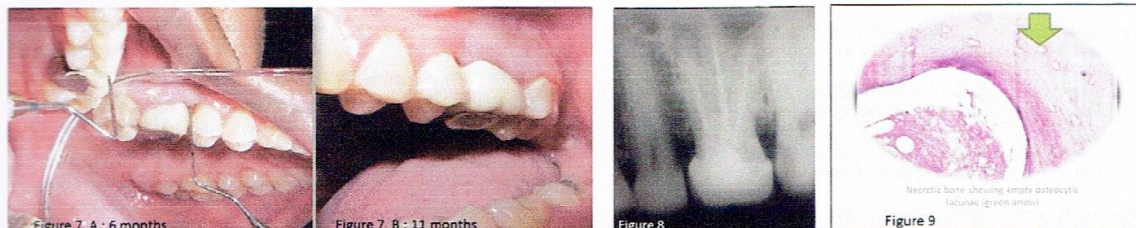


Figure 7 A : 6 months

Figure 7 B : 11 months

Figure 8

Figure 9

[Table/Fig-7a,b]: (a) Recall re-evaluation after 6 months (b) Recall re-evaluation after 11 months.

[Table/Fig-8]: Postoperative radiograph.

[Table/Fig-9]: Histopathological picture of bone Necrosis showing empty lacunae (Green arrow).

a result of bone necrosis. Persistence of periodontal pocket due to underlying bony defect was a predictable outcome since no regenerative procedure was done at the first surgery. Regenerative periodontal procedure was not performed during the first surgery but was planned at second surgery to define the regeneration treatment. Absence of local infection and formation of healthy bone was ensured for the bone graft uptake in the region. A resorbable GTR membrane resists its degradation and stay for the desired time only if it does not get infected in the local site in its early initial stage of regeneration. Considering present condition, a full thickness mucoperiosteal flap [Table/Fig-5a] was planned with placement of Demineralized Freeze Dried Bone Allograft along with a shaped and contoured resorbable regenerative periodontal membrane (Periocol GTR) to correct the defect [Table/Fig-5b]. The GTR membrane used was a resorbable one to eliminate further surgical trauma to the patient by avoiding surgical step for retrieval. After placement of bone graft, the membrane was secured with resorbable sutures (Vicryl 3-0) using anchor sutures [Table/Fig-6a&b]. The full thickness periodontal flap was secured with black silk (3-0) interrupted sutures and Periodontal dressing (Coe pak) was placed.

For the postoperative phase of both the surgeries, the patient was kept under a short antibiotic course (Amoxicillin 500mg + Clavulanic acid 125mg), two times daily for 3 days and an analgesic, anti-inflammatory (Acetofenac 100mg + Paracetamol 325mg), three times daily for 3 days. During the healing phase, the patient was instructed for good oral hygiene maintenance, which was supplemented with 0.12% chlorhexidine gluconate (10 ml) rinse twice daily. With a good long follow up of almost a year, the patient is totally asymptomatic regarding the treated tooth except for

a slight gingival recession [Table/Fig-7a&b]. The 9 months follow up radiograph showed bone formation in the bony defect [Table/Fig-8].

DISCUSSION

Endodontic-Periodontic lesions are challenging in diagnosis and prognosis. A number of factors contribute to formation of these lesions such as trauma, root resorptions, perforations, dental anomalies and in this case a faulty restoration. The immense advances in dental treatment have led to use of numerous medicaments and materials in various dental specialities. There have been reported cases in the literature exhibiting irreparable damage to soft and hard tissues of the dental apparatus [1-3] when these therapeutic foreign materials are not used within the confinements of the dental structures. Among such materials, dental amalgam is well known and widely applicable restoration for the posterior teeth; with its reported disadvantages when not placed correctly within the boundaries of the prepared cavity [4-6].

Advance technologies generating newer dental restorative materials are being widely used with excellent results. Perhaps, careful technique skills and accurate therapy if not provided with these materials, may lead to unfavourable sequelae [6,7]. The universally used amalgam might cause such a great destruction of bone reminds us to use these materials cautiously and this also recalls the toxicity as regards to other materials which when comes in direct contact with bone could considerably harm it [1].

Differential diagnosis of any lesion stands prime priority because misdiagnosis may guide the treatment plan towards uncertain

outcomes leading to false or unnecessary treatment of the lesion. Such misdiagnosis may curtail the actual prognosis of the vital tissues. Radiological findings of the present case suggest a few lesions which may be confused with: Lateral periodontal cyst (LPC), keratocystic odontogenic tumours (KOT). Lateral periodontal cyst (LPC) is a non-inflammatory cyst on the lateral surface of the root of a vital tooth [8]. LPC has its own cardinal features, clinically and radiographically [9-11]. KOTs must be distinguished from similar lesions since these are aggressive and following surgical elimination may recur with high rate. Additionally pseudocysts, gingival cyst, radiolucent odontogenic tumours and lateral radicular cyst must also be considered in differential diagnosis of similar lesions like Lateral Periodontal cyst [12].

The present case was close to the diagnosis of Lateral Periodontal cyst radiographically but there was an absence of well-defined cortication around the lesion. The lesion being symptomatic with inflammatory components and present in the maxilla, adjacent to a non-vital molar ruled out LPC. This case was of a concomitant lesion with isolated endodontic and periodontic lesions. Both periapical and the periodontal lesions were treated separately as they were not directly connected. Endodontic treatment was considered before periodontic treatment to make the tooth asymptomatic and decrease the patient's discomfort. In this case report, the osteonecrosis was profound and the fragment of bone embedded in the granulation tissue was sent for histopathology and later confirmed as bone necrosis [Table/Fig-9]. For the treatment of osteonecrosis, the only remedy left is reflection of periodontal flap and removal of the necrosed part of bone which is an irreversible loss to the dental apparatus [13].

Guided tissue regeneration is a time tested and proven method to correct periodontal bony defects [14]. Regenerative periodontal therapy aims at restoring the tooth's supporting periodontal tissues. The combination of barrier membranes and grafting materials may result in histological evidence of periodontal regeneration, predominantly bone repair [15]. In the present case, the incorrect restoration was the primary aetiology for the periodontal injury. Hence, it was suitable to plan a periodontal regeneration therapy which was perhaps more promising after eliminating the aetiology. Infection has been considered a major cause of incomplete healing with GTR. Presence of infection at the recipient site may invariably cause a higher degree chance for rejection of graft. The ability of periodontal pathogens to produce cytotoxic products and gingival inflammation probably inhibits the coronal migration of periodontal fibroblasts on the tooth surface [16,17].

Amalgam restorations are used successfully since a century with its proven clinical longevity. But dental amalgam was identified adversely due to its mercury toxicity [18,19] and are also known to cause some local adverse effects if not properly contoured proximally especially in the cervical region. In a diseased gingival state due to subgingival amalgam restorations, the gingival health can be improved by correcting the overhanging margins [20]. Also, general health complaints have known to be resolved after removal of improper amalgam restorations [21].

There have been earlier reported cases of localised alveolar bone necrosis due to dental materials [22]. However, even histologic studies have confirmed that amalgam has the greater potential as compared to other materials to cause epithelial attachment lesions if placed near the soft tissues in the crevicular margins [23]. Based on treatment plan, Grossman classified endo-perio lesions into 3 types: Type 1 - Requiring endodontic treatment only; Type 2 - Requiring periodontal treatment only and; Type 3 - Requiring combined endo-perio treatment [24]. Many studies have shown satisfactory root canal disinfection by using rotary systems [25-27].

The use of laser radiation in disinfection of the root canal has also shown good results in addition to routine ProTaper rotary file system [28].

CONCLUSION

The report emphasises the importance of restoration of proper contact and contour to establish the healthy state of teeth and surrounding periodontal complex. Treatment and prognosis of Endodontic-Periodontic lesions differ, while accurate diagnosis of each specific condition and locating its aetiology is the primary key to resolve such lesions. Recent advances have equipped us with treatment modalities that can be utilised to correct any iatrogenic effects of various dental treatments but preserving the existing dental soft and hard tissues should be the primary objective during dental therapy.

REFERENCES

- Jeffcoat MK, Howell TH. Alveolar Bone destruction due to overhanging amalgam in Periodontal disease. *J Periodontol*. 1980;51:599-602.
- Fanibunda KB. Adverse response to endodontic material containing paraformaldehyde. *Br Dent J*. 1984;157(7):231-35.
- Sedghizadeh PP, Stanley K, Caligiuri M, Hofkes S, Lowry B, Shuler CF. Oral bisphosphonate use and the prevalence of osteonecrosis of the jaw. An institutional inquiry. *JADA*. 2009;140:61-66.
- WG Reeves. Restorative margin placement and Periodontal health. *J Prosthet Dent*. 1991;66:733-36.
- Lang NP, Keil RA. Clinical and microbiological effects of subgingival restorations with overhanging or clinically perfect margins. *J Clin Periodontol*. 1983;10:563-78.
- Pack ARC, Coxhead LJ, McDonald BW. The prevalence of overhanging margins in posterior amalgam restorations and periodontal consequences. *J Clin Periodontol*. 1990;17:145-52.
- Arneberg P, Silness J, Nordbo II. Marginal fit and cervical extent of class II amalgam restorations related to periodontal condition. *J Periodontol Res*. 1980;15:669-77.
- Kramer IR, Pindborg JJ, Shear M. WHO Histological Typing of Odontogenic Tumours. 2nd ed. Geneva: Springer-Verlag; 1992. pp.34-118.
- Soares de Lima AA, Naval Machado MA, Braga AM, De Souza MH. Lateral periodontal cyst: Aetiology, diagnosis and clinical significance. A review and report of case. *Rev de Clin Pesqui Odontol*. 2005;11:55-59.
- Atini M, Shear M. The lateral periodontal cyst: An update. *J Oral Pathol Med*. 1992;21:245-50.
- Angelopoulou E, Angelopoulos AP. Lateral periodontal cyst. Review of the literature and report of a case. *J Periodontol*. 1990;61:126-31.
- de Andrade M, Silva AP, de Moraes Ramos-Perez FM, Silva-Sousa YT, da Cruz Perez DE. Lateral periodontal cyst: Report of case and review of the literature. *Oral Maxillo fac Surg*. 2012;16:63-67.
- Adornato MC, Morcos I, Rozanski J. The treatment of Bisphosphonate-associated osteonecrosis of the jaws with bone resection and autologous platelet-derived growth factors. *JADA*. 2007;138(7):971-77.
- Chen CC, Wang HL, Smith F, Glickman GN, Shyr Y, O'Neal RB. Evaluation of a Collagen Membrane With and Without Bone Grafts in Treating Periodontal Intraony Defects. *J Periodontol*. 1995;66:838-47.
- Sculean A, Nikolaidakis D, Schwarz F. Regeneration of periodontal tissues: combinations of barrier membranes and grafting materials – biological foundation and preclinical evidence: A systematic review. *J Clin Periodontol*. 2008;35:106-16.
- AB NOVAES, DB PALIOTO, PF de ANDRADE, JT MARCHESAN. Regeneration of Class II Furcation Defects: Determinants of Increased Success. *Braz Dent J*. 2005;16(2):87-97.
- Nowzari H, Matian F, Slots J. Periodontal pathogens on polytetra fluoroethylene membrane for guided tissue regeneration inhibit healing. *J Clin Periodontol*. 1995;22:469-74.
- Needleman HL. Mercury in Dental Amalgam—A Neurotoxic Risk? *JAMA*. 2006;295:1775-83.
- Shenker BJ, Maserejian NN, Zhang A, McKinlay S. Immune Function Effects of Dental Amalgam in Children: A Randomized Clinical Trial. *JAMA*. 2008;309:1496-505.
- Rodríguez-Ferrer HJ, Strahan JD, Newman HN. Effect on gingival health of removing overhanging margins of interproximal subgingival amalgam restorations. *J Clin Periodontol*. 1980;7:457-62.
- Slursen TT, Lygre GB, Dalen K, Helland V, Laegreid T, Svahn J, Lundekvam BF, Bjorkman L. Changes in health complaints after removal of amalgam fillings. *J Oral Rehabil*. 2011;38:835-48.
- Ozmeric N. Localised alveolar bone necrosis following the use of an arsenical paste. A case report. *Int Endod J*. 2002;35:295-99.

- [23] Zogheib CM, Mokbel N, Naaman NB. Amalgam, composites and comonomers: a comparative histologic study of periodontal tissues (Part 2). *Rev Belge Med Dent.* 2008;63(1):36-44.
- [24] Mittal N, Hegde. Text Book of Endodontics. 1st edition, EMMESS Medical Publisher; 2009: 309- 310.
- [25] Siqueira JF Jr, Rocas IN, Santos SR, Lima KC, Maganhaes FA, de Uzeda M. Efficacy of instrumentation techniques and irrigation regimens in reducing the bacterial population within root canals. *J Endod.* 2002;28: 181-84.
- [26] de Rossi A, Silva LA, Leonardo MR, Rocha LB, Rossi MA. Effect of rotatory or manual instrumentation, with or without a calcium hydroxide 1% chlorhexidine intracanal dressing, on the healing of experimentally induced chronic periodontal lesions. *Oral Surg Oral Med Oral Pathol Oral Radiol/Endod.* 2005;99:628-36.
- [27] Reiner VR, Gomes RP, Sena NT, et al. Efficacy of various concentrations of NaOCl and instrumentation techniques in reducing *Enterococcus faecalis* within root canals and dentinal tubules. *Int Endod J.* 2006;39: 10-17.
- [28] Hegde MN, Hegde ND, Nagesh SC. Lasers in management of endo-perio lesion - A case report. *Arch Oral Biol.* 2011;1:215-18.

PARTICULARS OF CONTRIBUTORS:

1. Assistant Professor, Department of Periodontics, Nair Hospital Dental College, Maharashtra, India.
2. Professor and Head, Department of Periodontics, Nair Hospital Dental College, Maharashtra, India.
3. Associate Professor, Department of Prosthodontics, Nair Hospital Dental College, Maharashtra, India.
4. Assistant Professor, Department of Conservative Dentistry and Endodontics, Nair Hospital Dental College, Maharashtra, India.

NAME, ADDRESS, E-MAIL ID OF THE CORRESPONDING AUTHOR:

Dr. Pimpale Sandeep K.
203, Kalas Sarovar, Plot no. 500, Sector no. 5, Sanpada, Navi Mumbai-400705, India.
E-mail : sandeepdentist3@gmail.com

Date of Submission: **Jan 02, 2015**
Date of Peer Review: **Jan 19, 2015**
Date of Acceptance: **Apr 17, 2015**
Date of Publishing: **May 01, 2015**

FINANCIAL OR OTHER COMPETING INTERESTS: None.