



Comparison of the Soft Tissue Healing with Scalpel and Laser: A Case Report

Dr. Payal Pitambar Ramteke, Dr. Mala Dixit Baburaj

(PG Student, Dept. of Periodontics, Nair Hospital Dental College, Mumbai)

(Professor and Head of the Department, Dept. of Periodontics, Nair Hospital Dental College, Mumbai)

Submitted: 25-09-2021

Revised: 28-09-2021

Accepted: 03-10-2021

ABSTRACT: Fibroma is the most common benign lesion of the oral cavity. The most common reasons are trauma and irritation. Excision is one of the treatment modalities for this soft tissue lesion [1]. This article is about the clinical presentation, diagnosis, and histopathological picture of two fibromas on the right buccal mucosa of the same patient. We excised one of the lesions with the conventional technique i.e. with the scalpel and the other one with the laser; and compared, clinical and histopathological pictures, throughout the follow-up, and also, the healing by these modes of excision.

Keywords: Fibro-epithelial Hyperplasia, Diode laser, TMJ (Temporomandibular Joint), H and E (Hematoxylin and Eosin).

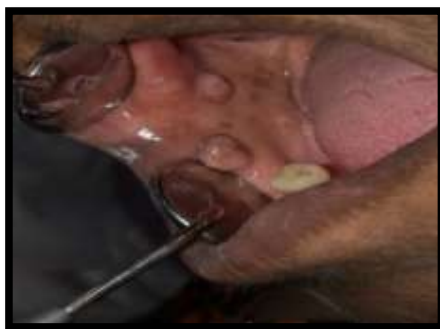I. INTRODUCTION:

Amongst the soft tissue lesions in the oral cavity, fibroma is the most common soft tissue lesion. The lesion mostly presents as painless, sessile, or pedunculated, round to oval in shape [2-

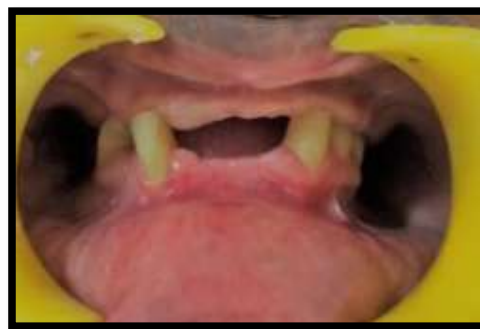3]. There are various reasons for the occurrence of fibromas in the oral cavity like chronic trauma, disturbed occlusal forces, malocclusion, crowding of teeth, irritation, ill-fitting prosthesis, unpolished and overhanging restorations, unpolished dentures [4]. Chronic mucosal irritation resulting from ill-fitting dentures may lead to irritational fibroma and it may consider as one of the risk factors for the development of oral cancer [5].

Case Report:

A 56 year old, partially edentulous female patient reported to the Department of Periodontics, Nair Hospital Dental College, Mumbai, India, with a chief complaint of two soft tissue masses on the right cheek since 7-8 months. She was apparently all right until 8 months back, when she noticed two soft tissues growth on her right buccal mucosa which was interfering with her ability to eat and chew normally. The soft tissues growth was not associated with any pain or suppuration. They gradually increased to the present size.



Intra-oral pictures fig: a



Intra-oral pictures fig: b



Normal extra-oral findings fig: c

On dental examination, it was found that she was partially edentulous with a history of using ill-fitted dentures for about a year. It was irritating to her buccal mucosa, so she stopped wearing the denture by herself. Calculus deposits were seen. There were no adverse habits. Her gait was normal, she was mesomorphic with pulse rate, blood pressure and other vitals were normal.

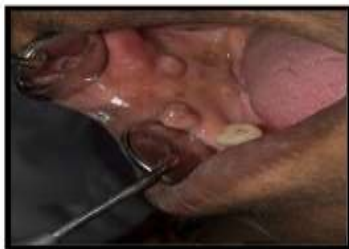One soft tissue growth was located near the angle of the mouth and another one was behind the anterior growth on the buccal mucosa (figure: b). On extraoral examination, no abnormality of the face was detected. The face was bilaterally symmetrical. Lymph nodes were not palpable, suggesting no underlying infection was associated with them. There was no tenderness, clicking, or deviation of TMJ. The patient was systemically healthy; there was no history of any underlying disease.

On intraoral examination, the “lesion 1” was 6mm×5mm in size, oval in shape, reddish-pink in color, lobulated sessile mass located on the right

buccal mucosa behind the anterior lesion, and “lesion 2” was of 9mm×7mm, round to oval in shape, reddish-pink in color, soft sessile growth located near the angle of mouth. (Figure: So, we came to a provisional diagnosis of Irritational fibromas on the right buccalmucosa.

For this patient, we planned scaling and root planning first then oral hygiene instructions were given. The proper brushing technique was demonstrated to the patient. Then, we prescribed 0.2 % Chlorhexidine mouthwash twice daily for 15 days. The patient was recalled for follow-up after 1 week.

We noticed there were no reductions in size or changes in the shape of both the lesions. Then we sent the patient for VELscope examination to find out, if any, dysplastic changes were associated with it. VELscope report showed that there were no dysplastic changes in both the lesions (fig: e). Then, we sent the patient for blood investigations and all the values were within the physiological limit.



Clinical picture of the lesions. fig: d



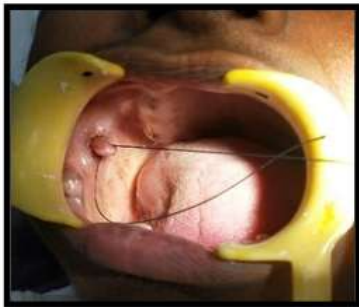No dysplastic changes on VELscope fig: e



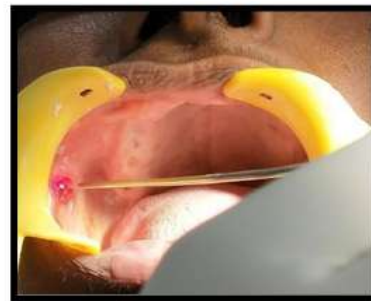We planned surgical excision for both lesions. Local anesthesia was administered to “lesion 1”, and then we sutured the lesion for better handling (figure: f). A soft tissue diode laser of 2.5 W fiber tip was used in contact mode and moved in brushing strokes (figure: g). The tissue was removed slowly and gently in a sweeping motion, remnants of tissue were cleaned with gauze soaked in saline and maintained hydration throughout the excision.

Then, “lesion2” was anesthetized and sutured for better traction (figure: h).

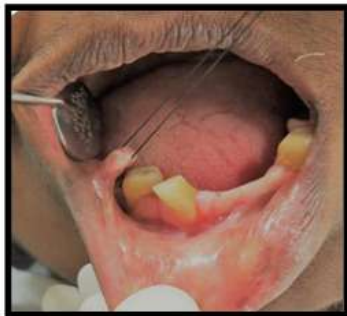Excision of this lesion was done with the help of a conventional scalpel (figure: I). Immediate after excision bleeding was seen with scalpel excision while arrested bleeding was noted with the laser excision (figure). Both the excised tissues were measured (figure j and k). After excision, both the tissues were sent for histopathological investigations.



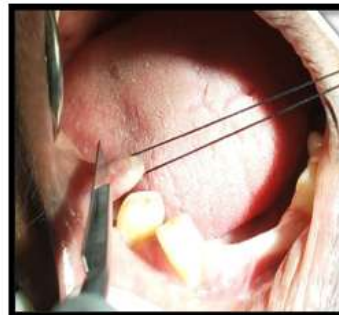Sutured lesion for better traction fig: f



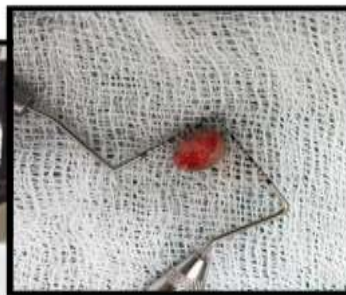Excision with Laser fig: g



Sutured lesion for better handling fig: h

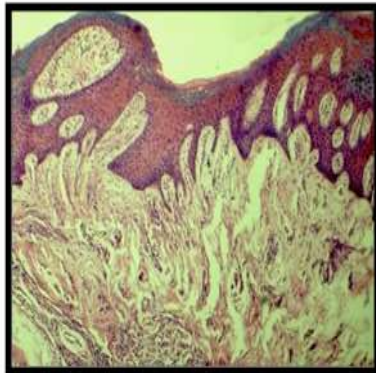


Excision with Scalpel fig: i

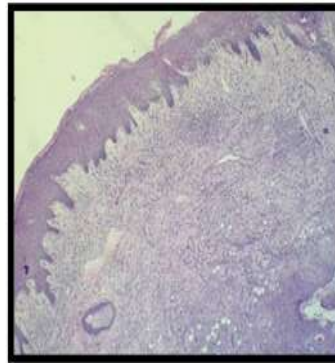

Excised tissue by Scalpel fig: k

Soft tissue Diode laser of 2.5



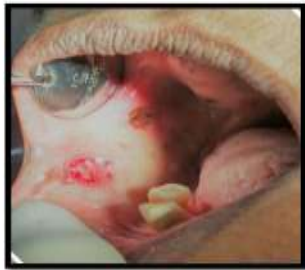Histopathological section of tissue excised by laser fig: l



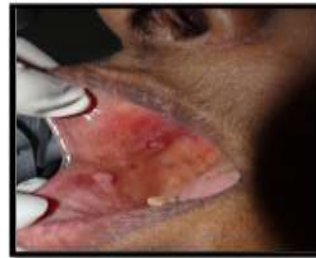Histopathological section of tissue excised by scalpel fig: m

H and E histopathological picture of a scalpel and laser excision showed Stratified squamous epithelium and numerous plump fibroblast and dense collagen fiber bundles along with blood vessels and few inflammatory cells. So, overall clinical features were suggestive of "Fibroepithelial Hyperplasia". No epidermal destruction was noted with scalpel biopsy (fig: m).

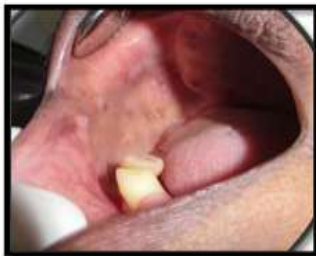While in the histopathological picture of laser excision, there were warming, welding, denatured proteins (fig: l). The cellular tissues showed carbonization and vaporization. Also, epidermal destruction and marginal charring were observed with laser biopsy. These effects are the result of energy transmitted by a laser beam.



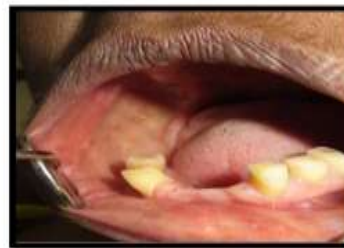Immediate Post-Operative View



7th day post-operative view fig: n



14th day post-operative fig: o



21st day post-operative fig: p

Wound healing was clinically evaluated over 7 days, 14 days, 21 days after the surgical procedure with the help of WHI (Wound Healing

Index) by Landry.

Postoperatively, the healing process was monitored based on clinical signs and symptoms,



pain, induration or pus discharge, etc.

On the 7th day post-operative, the patient came for follow-up with scab formation on scalpel biopsy wound. There were no signs of infection at both the sites (fig: n). The blood vessels and lymphatics were sealed and extravasation of fluids was noticed at the laser excision site. A denatured collagen layer was observed which acted as a natural barrier for wound isolation and it further reduced pain and maintained wound asepsis.

On the 14th day, it appeared that the site with scalpel excision was healing faster than the site with laser excision. Both the sites could barely differentiate from each other. After copious betadine irrigation, the patient was asked to report after a week for follow-up (fig: o).

On the 21st day (figure), we noticed that both the sites healed uneventfully with no scarring, no pigmentation or induration or pus discharge or tenderness noticed at both the sites. We kept the patient on follow-up for any relapse growth or fibrotic changes at the surgical site. But no such events were noticed throughout the follow up (fig: p).

II. DISCUSSION:

Treatment of benign oral lesion is complete excision of that lesion and rule out details of biopsy of that lesion.[6] Diagnostic tools like VELscope and histopathological findings help to reach the diagnosis of the lesion keeping in mind the clinical findings also [7-8]. It should differentiate clinically and histopathologically from other lesions like sarcomatous and neoplastic lesions [8-10].

In this excisional biopsy, the site with scalpel excision showed more bleeding as compared to the site with laser excision. While arrested bleeding was associated with the laser excision site. Diode laser provided better patient comfort due to arrested bleeding, painless procedure, and no post-operative swelling, and also reduced intra-operative time. The laser causes thermal damage to tissues but it can be taken care of by keeping tissues hydrated throughout the procedure and by using a low-power laser. It seems that both techniques are equally effective for biopsies of benign lesions of the oral cavity. However, the histological picture may be damaged by laser excision which can be minimized by using low power laser and atraumatic excision.

III. CONCLUSION:

For early healing, scalpel excision is better than laser excision but patient compliance is better with laser excisions. So, the choice of technique

should depend on the condition of the patient, their compliance, clinician skills and experience, and the type and extent of the lesion. The goal should be atraumatic and uneventful excision and minimal damage to the tissue. Vital structures should be prevented from damage.

ACKNOWLEDGEMENT:

We would like to acknowledge the Department of Oral Pathology and Microbiology, Nair Hospital Dental College for their contribution.

REFERENCES:

- [1]. Esmeili T, Lozada-Nur F, Epstein J. Common benign oral soft tissue masses. *Dent Clin North Am.* 2005 Jan;49(1):223-40, x. doi: 10.1016/j.cden.2004.07.001. PMID: 15567370.
- [2]. Reddy V, Saxena S, Saxena S, Reddy M. Reactive hyperplastic lesions of the oral cavity: A ten year observational study on North Indian Population. *J Clin Exp Dent.* 2012 Jul 1;4(3):e136-40. doi: 10.4317/jced.50670. PMID: 24558543; PMCID: PMC3917636.
- [3]. Saharan K, Shivaprasad S, Poornima R, Ashok L. Irritational fibroma of gingiva in a young female: A case report. *J Med Radiol Pathol Surg* 2017;4: 15-17.
- [4]. Madhusudan AS, Gupta S, Sowmya GV. Focal Fibrous Hyperplasia: Report of two Cases. *Int J Dent Clinics.* 2011;3(1):111-2.
- [5]. Singh S, Subbareddy VV, Dhananjaya G, Patil R. Reactive fibrous hyperplasia associated with a natal tooth - A Case Report. *J Indian Soc Pedo Prev Dent* 2004;22:183-6
- [6]. Barker DS, Lucas RB. Localised fibrous overgrowths of the oral mucosa. *Br J Oral Surg.* 1967;5: 86-92
- [7]. Jinal D, Krishna D, Gaurav B, Dharmesh V. Traumatic fibroma - A review and report of two cases. *Int J Current Res.* 2017; 9: 52004-52006.
- [8]. Bilichodmath S, Sambhashivaiah S. Traumatic Fibroma: A Case Series. *J Health Sci Res* 2016;7(1):28-31.
- [9]. Kfir Y, Buchner A, Hansen LS. Reactive lesions of the gingiva. A clinic-pathological study of 741 cases. *J Periodontol* 1980;51:655-661.
- [10]. Martín-Granizo R, Sanchez-Cuellar A, Falahat F. Cemento-ossifying fibroma of the upper gingivae. *Otolaryngol Head Neck Surg.* 2000;122(5):775.